

Received: 2015.04.12
Accepted: 2015.07.13
Published: 2015.12.02

Anthropometric Study of the Piriformis Muscle and Sciatic Nerve: A Morphological Analysis in a Polish Population

Authors' Contribution:
Study Design A
Data Collection B
Statistical Analysis C
Data Interpretation D
Manuscript Preparation E
Literature Search F
Funds Collection G

ABDG 1 Robert Haładaj
C 2 Mariusz Pingot
DF 3 Michał Polguj
BEF 1 Grzegorz Wyśiadecki
ADEFG 1 Mirosław Topol

1 Department of Normal and Clinical Anatomy, Interfaculty Chair of Anatomy and Histology, Medical University of Łódź, Łódź, Poland
2 Therapeutic Pedagogy Laboratory, Jan Kochanowski University in Kielce, Piotrków Trybunalski Branch, Piotrków Trybunalski, Poland
3 Department of Angiology, Interfaculty Chair of Anatomy and Histology, Medical University of Łódź, Łódź, Poland

Corresponding Author: Michał Polguj, e-mail: michal.polguj@umed.lodz.pl
Source of support: Departmental sources

Background: The aim of this study was to determine relationships between piriformis muscle (PM) and sciatic nerve (SN) with reference to sex and anatomical variations.





Material/Methods: Deep dissection of the gluteal region was performed on 30 randomized, formalin-fixed human lower limbs of adults of both sexes of the Polish population. Anthropometric measurements were taken and then statistically analyzed.

Results: The conducted research revealed that, apart from the typical structure of the piriformis muscle, the most common variation was division of the piriformis muscle into two heads, with the common peroneal nerve running between them (20%). The group with anatomical variations of the sciatic nerve course displayed greater diversity of morphometric measurement results. There was a statistically significant correlation between the lower limb length and the distance from the sciatic nerve to the greater trochanter in the male specimens. On the other hand, in the female specimens, a statistically significant correlation was observed between the lower limb length and the distance from the sciatic nerve to the ischial tuberosity. The shortest distance from the sciatic nerve to the greater trochanter measured at the level of the inferior edge of the piriformis was 21 mm, while the shortest distance to the ischial tuberosity was 63 mm. Such correlations should be taken into account during invasive medical procedures performed in the gluteal region.

Conclusions: It is possible to distinguish several anatomical variations of the sciatic nerve course within the deep gluteal region. The statistically significant correlations between some anthropometric measurements were only present within particular groups of male and female limbs.

MeSH Keywords: **Anatomic Variation • Buttocks • Piriformis Muscle Syndrome • Sciatic Nerve**

Full-text PDF: <http://www.medscimonit.com/abstract/index/idArt/894353>

 3039  3  6  24



Background

The piriformis muscle (PM) is located posterior to the hip joint and passes out of the pelvis through the greater sciatic foramen, dividing it into two topographic areas of utmost clinical importance: suprapiriform and infra-piriform foramina. Due to the fact that a large number of invasive medical procedures are performed in the gluteal region, knowledge of the typical and variant anatomical relationships between the PM and sciatic nerve (SN) may be crucial to ensure the best outcome. The PM may be also associated with etiopathogenesis of pain syndrome whose symptoms resemble sciatica and which is called piriformis syndrome. The syndrome incidence is estimated at 6% in patients with sciatica symptoms [1]. The traditional approach describes piriformis syndrome as a neuromuscular disorder classified as compression neuropathy, caused by compression on the SN at the level of the PM [2–5]. However, there are some patients with abdominal pain of uncertain etiology (e.g., some anatomical variants of vasculature of the abdomen) that may lead to unnecessary investigation and intervention [6]. Piriformis syndrome poses a considerable diagnostic problem, and data on its etiopathogenesis, especially with regard to its anatomical conditions, are still scarce.

Upon detailed literature review, the authors of the present work have found no anatomy research in which morphometric differences between a group with a typical PM morphology and a typical SN course in the infra-piriform foramen and a group with anatomical variations of both these structures would be statistically analyzed. There is also little data on these relationships with reference to sex.

The article aims at: 1) studying the incidence of anatomical variations in the SN course in relation to the piriformis; 2) taking precise anthropometric measurements of selected PM and SN parameters; and 3) comparing the measurement results of the group with a typical SN course and the group with variations of the SN, as well as comparing the results found in male and female limbs.

Material and Methods

Thirty randomized, formalin-fixed human lower limbs of adults of both sexes were studied. The specimens were 14 limbs of women and 16 limbs of men, 13 of which were right limbs and 17 left ones. The Bioethics Commission of the Medical University of Lodz issued a consent for the study (consent no. RNN/671/14/KB).

Deep dissection was performed in the gluteal region. Upon visualization of the structures located deep to the gluteus maximus muscle, the PM morphology was evaluated. Special

attention was paid to the SN course in the infra-piriform foramen and its relation to PM.

The next stage has consisted in precise morphometric measurements of PM parameters (width – WPM, length of the upper edge – LUEPM, length of the lower edge – LLEPM) and SN location from palpable bony landmarks (distance between the lateral edge of the SN and the greater trochanter – LESN-GT, distance between the medial edge of the SN and the apex of the ischial tuberosity – MESN-IT). When determining the landmarks for measurements, the methodology applied by Güvençer et al. [2] has been used, with modifications necessary for the purposes of this study. To complete the data, the following parameters were measured and statistically analyzed: length of the lower extremity (LLE) from the greater trochanter to the lower edge of the lateral malleolus, thigh length (TL) from the greater trochanter to the knee-joint fissure, distance between the posterior superior iliac spine and the greater trochanter (PSIS-GT), distance between the posterior superior iliac spine and the apex of the ischial tuberosity (PSIS-IT), distance between the apex of the ischial tuberosity and the greater trochanter (IT-GT) as well as length at which the SN crosses the lower edge of PM (LSN-LPEM). The measurements have been taken along straight lines, with Stanley PowerLock® Tape Rule (Stanley Tools Product Group, New Britain, the United States) and Digimatic Caliper (Mitutoyo Corporation, Kawasaki-shi, Kanagawa, Japan). Each measurement was taken twice, accurate to within 1 mm (with the exception of the SN measurements, which were accurate to within 0.1 mm); the average of both measurements was accepted as the final result.

Individual parameters have been assessed in the anthropometric study and their designations are presented in Table 1.

The gathered data have been statistically analyzed. For the purposes of the analysis, the specimens have been divided into two groups: the first one with a typical PM morphology and a typical SN course in the infra-piriform foramen and the second one with variations in the area. Standard descriptive statistics has been used in the study. Distribution normality of the variables has been assessed with the Shapiro-Wilk test. Despite the small size of the sample, deviation from distribution normality has been noted only for the LLEPM variable (for both groups), and for WPM in the group with a typical PM and PSIS-GT morphology and in the group with anatomical variations. This has made it possible to use parametric methods for assessment of significance of differences between the groups (in the case at hand – Student's t-test) for the majority of variables. For variables with deviations from the normal distribution the nonparametric Mann-Whitney test has been applied. The next stage has consisted in assessment of correlations between the variables with a specific correlation coefficient: Spearman's rho. The collected measurements have

Table 1. Parameters of anthropometric measurements.

No.	Measured parameter	Designation
1	Length of the lower extremity	LLE
2	Thigh length	TL
3	Distance between the posterior superior iliac spine and the greater trochanter	PSIS-GT
4	Distance between the posterior superior iliac spine and the apex of the ischial tuberosity	PSIS-IT
5	Distance between the apex of the ischial tuberosity and the greater trochanter	IT-GT
6	Width of the piriformis muscle	WPM
7	Length of the upper edge of the piriformis muscle	LUEPM
8	Length of the lower edge of the piriformis muscle	LLEPM
9	Distance between the lateral edge of SN (at the point where it crosses the lower edge of PM) and the greater trochanter	LESN-GT
10	Distance between the medial edge of SN (at the point where it crosses the lower edge of PM) and the apex of the ischial tuberosity	MESN-IT
11	Length at which SN crosses the lower edge of PM	LSN-LEPM

also been statistically analyzed with regard to sex. The significance level adopted in the analysis is $\alpha < 0.05$. The calculation was made with IBM SPSS Statistics 21.0. During data interpretation only correlations of the potential clinical or cognitive significance were taken in consideration.

Results

Anatomical variations of the piriformis muscle.

Upon analysis of the PM morphology after it passes out of the pelvis, three variations of the muscle have been observed.

Variation I includes the cases with a typical PM morphology, where the muscle is pear-shaped (Figure 1). This PM morphological type has been observed in 21 specimens (70%), more specifically in 11 male limbs and in 10 female limbs.

Variation II covers the cases where PM is divided into two parts with the common peroneal nerve running between them (Figure 2). This variation has been found in six specimens (20%), three of which are male and three female. One of the cases classified as variation II has presented a distinct fusion of a tendon of one of the PM parts with the inferior gemellus muscle (Figure 2).

Variation III encompasses the limbs in which there is a fusion of PM with the gluteus medius muscle (Figure 3). The variation has been found in three cases (10%), more specifically in two

male limbs and in one female limb. Due to the fusion of PM and the gluteus medius, the superior gluteal nerve and superior gluteal vessels run between fibres of the fused muscles.

Variations of the sciatic nerve with reference to piriformis muscle

In the study material, a typical course of the SN (a single trunk in the infra-piriform foramen) has been observed in 20 limbs (66.7%), 11 of which are male and nine female (Figure 1). 17 out of the limbs (56.6%) have displayed a typical PM morphology, whereas three of the limbs (10%) have PM fused with the gluteus medius (Figure 3).

The variation in which the common peroneal nerve runs through PM (Figure 2) was found in six limbs (20%) – three male and three female. This variation covered the cases where PM was divided into two parts with the common peroneal nerve running between them.

Three limbs (10%), on the other hand, have displayed a variation in which two SN roots merge below the PM inferior edge into one trunk. This morphology has been found in one male limb and two female limbs, with PM displaying a typical morphology.

A rare variation with common peroneal nerve running within suprapiriform foramen and tibial nerve running within infra-piriform foramen (Figure 4) was found in one male limb (3.3%).

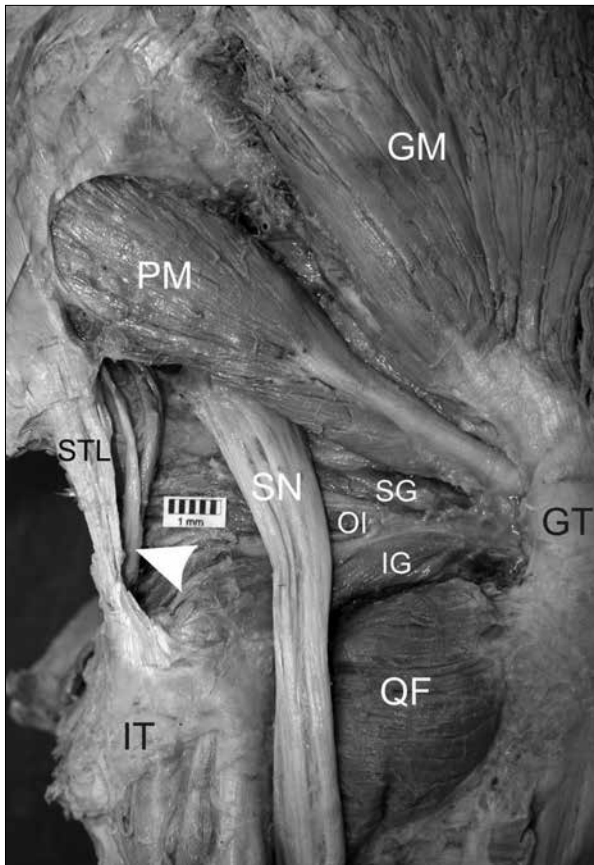


Figure 1. A typical morphology of the piriformis muscle and a typical course of the sciatic nerve in the infra-piriform foramen. The white arrowhead indicates the pudendal nerve. GM – gluteus medius muscle, GT – greater trochanter, IG – inferior gemellus, IT – ischial tuberosity, OI – obturator internus, PM – piriformis muscle, QF – quadratus femoris, SN – sciatic nerve, SG – superior gemellus, STL – sacrospinous ligament.

Anthropometric measurements

For the purposes of statistical analysis, the study material has been divided into two groups depending on SN relationships to the piriformis. Specimens with a typical course of the SN have been classified in the first group. Specimens displaying atypical course of the SN in the greater sciatic foramen have been classified in the second group.

Analysis of the statistical data (Table 2) indicates that the groups do not significantly differ in the median, although slightly higher levels have been recorded for the group with the anatomical variations. The ‘variations’ group displayed greater diversity of results (Figure 5). Comparing the two populations using an adequate test does not, however, confirm significance of the differences between them from the perspective of the variables at hand.

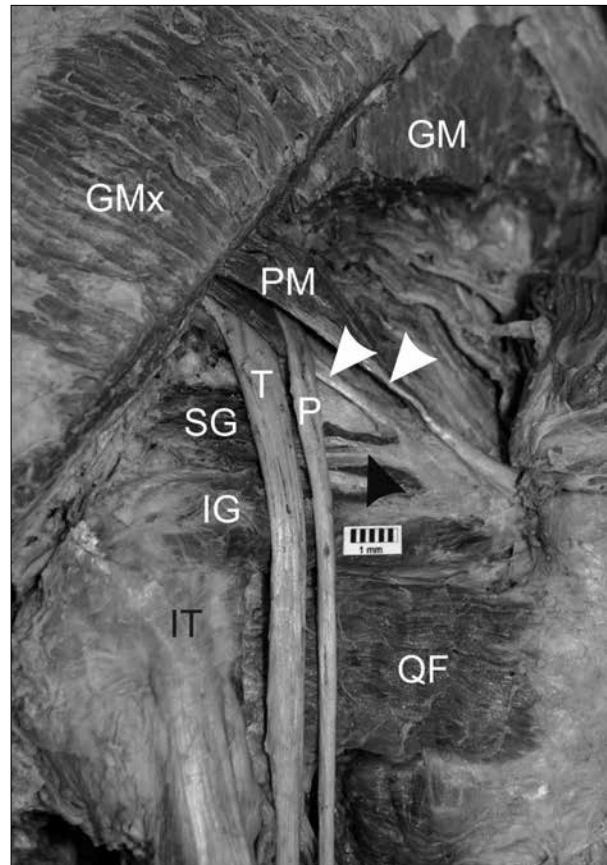


Figure 2. The common peroneal nerve running through the piriformis muscle. The white arrowheads indicate two parts of the piriformis with the common peroneal nerve running between them. The black arrowhead indicates a tendon of the superior gemellus muscle, fused with the piriformis tendon. GM – gluteus medius muscle, GMx – gluteus maximus muscle, IG – inferior gemellus, IT – ischial tuberosity, P – common peroneal nerve, PM – piriformis muscle, QF – quadratus femoris, SG – superior gemellus, T – tibial part of the sciatic nerve.

The conducted analysis allows for drawing a conclusion that there is a significant positive correlation between selected piriformis parameters on the one hand, and certain anthropometric measurements on the other, in the typical PM morphology group. The higher (on average) PSIS-IT, PSIS-GT and IT-GT, the bigger WPM. Analogical, and at the same time stronger, relationships have been observed for LLEPM, whereas LESN-GT is significantly and positively correlated with PSIS-IT and PSIS-GT. Another significant positive correlation has been observed between LSN-LEPM and LLE. In the second group these regularities are weaker and not statistically significant. Generally, in the group with a typical PM morphology, there has been observed a distinct regularity that a higher level of one parameter corresponds to a higher level of the other.




Figure 3. Fusion of the piriformis and the gluteus medius muscle. The white arrowhead indicates the superior gluteal vessels, running between fibres of the two fused muscles. GM&PM – fusion of the two muscles, GT – greater trochanter, SN – sciatic nerve.

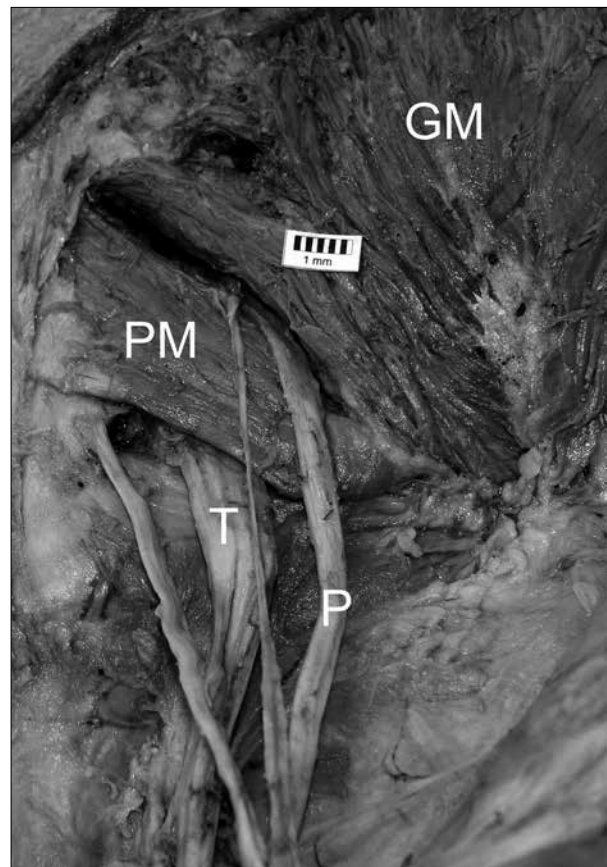


Figure 4. The common peroneal nerve running through the suprapiriform foramen. GM – gluteus medius muscle, P – common peroneal nerve, PM – piriformis muscle, T – tibial part of the sciatic nerve.

Assessment of the relationships between particular PM parameters (LUEPM, LLEPM, WPM) and selected SN parameters (LESN-GT, MESN-IT) has revealed slightly different configurations of relationships in the group with a typical course of the SN and the group with atypical course of the SN. Only the relationships between LESN-GT on the one hand, and LUEPM and LLEPM on the other, as well as between LSN-LPEM and WPM can be deemed statistically significant in the group with a typical SN course. In the second group none of the relationships has been statistically significant.

Table 3 contains basic descriptive statistics for the analyzed variables in the male specimens group and in the female specimens group. Sex-oriented statistical analysis of the gathered material revealed significant statistical differences in SN diameter measured along the lower edge of PM (the LSN-LPEM dimension) – the parameter has been higher to a statistically significant extent in the male limbs. PSIS-IT is another parameter found to be higher to a statistically significant extent in the male group.

In the male limbs, there has been a statistically significant positive correlation found between the length of the lower edge of PM (the LLEPM dimension) and the parameters PSIS-GT, IT-GT, LESN-GT, MESN-IT and LSN-LPEM. In the female limbs only the LESN-GT dimension has correlated to a statistically significant extent with the LLEPM parameter.

In the male limbs group there has been a statistically significant correlation observed between the length of the lower limb (LLE) and the distance from the lateral edge of the SN to the greater trochanter (LESN-GT). In this group also the LSN-LPEM parameter has been found to be positively correlated to a statistically significant extent with the IT-GT parameter. In the female limbs group there has been a statistically significant positive correlation observed between the length of the lower limb (LLE), as well as the thigh length (LT), and the distance from the SN to the apex of the ischial tuberosity (the MESN-IT parameter).

A comparison of dispersion of the selected variables in the male limbs group and in the female limbs group has been illustrated in Figure 6.

Table 2. Basic descriptive statistics for the analysed variables in the first group (a typical morphology of the piriformis muscle) and in the second group (with anatomical variations).

	Group 1					Group 2				
	Min [mm]	Max [mm]	Median [mm]	Arithmetic mean [mm]	SD [mm]	Min [mm]	Max [mm]	Median [mm]	Arithmetic mean [mm]	SD [mm]
LLE	683	824	738	739	45.8	638	805	764	747	61.1
TL	336	396	372	371	20.3	320	412	386	380	29.6
PSIS-IT	104	141	115	117	11	94	139	122	120	15.6
PSIS-GT	109	146	130	131	10.2	97	143	134	131	14.7
IT-GT	62	100	75	76	13	59	115	78	84	17.9
WPM	28	50	31	32	6	27	39	32	33	4.2
LUEPM	70	96	78	81	8	71	106	80	85	13.6
LLEPM	69	116	81	82	11.8	74	110	82	86	13.3
LESN-GT	21	50	35	37	9.7	22	52	41	39	10.4
MESN-IT	63	96	74	74	8.8	66	90	71	74	8.9
LSN-LEPM	11	27.7	16.9	17.6	4.8	10.1	32.5	22.8	22.2	7.5

Designations description as in Table 1.

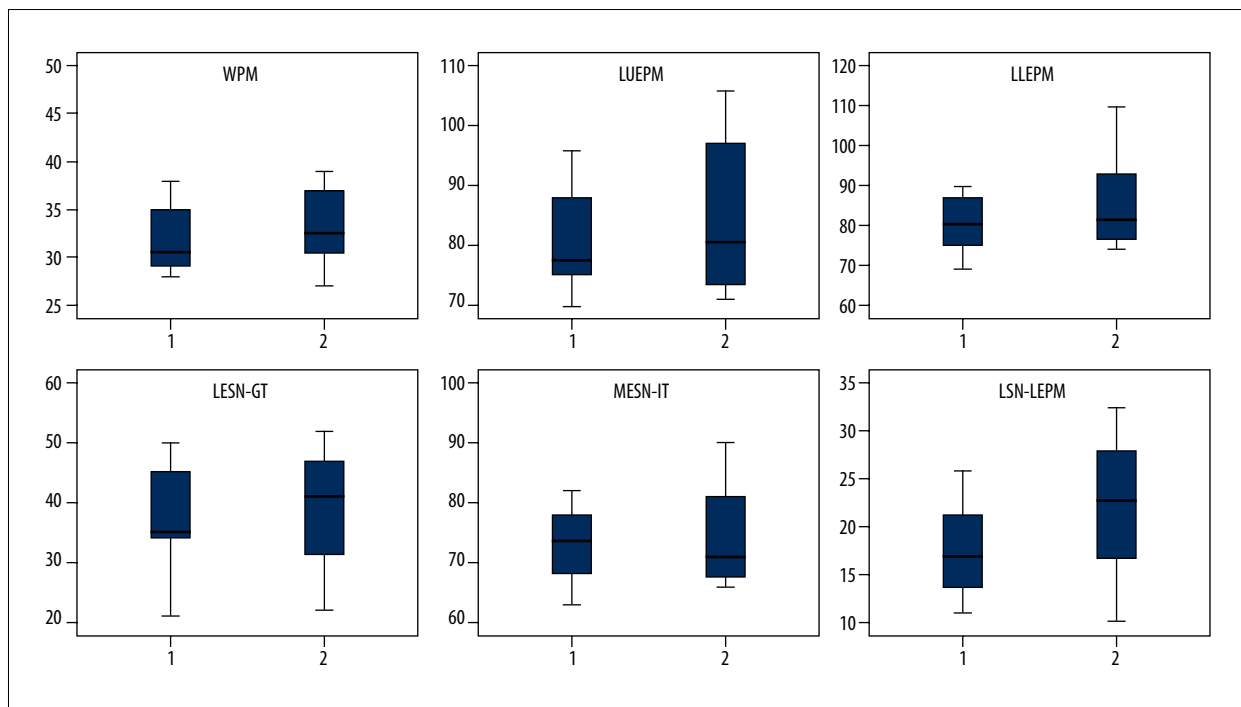


Figure 5. Comparison of dispersion of selected variables in the first group (a typical morphology of the piriformis) and in the second group (with anatomical variations).

Discussion

In 1937 Beaton and Anson introduced a modern detailed classification of SN course in relation to PM [7]. Bergman claims

that the most common PM variation is its division into two parts [8]. This variation is related to high division of the SN, with the peroneal portion of the nerve emerging between the two parts of PM [8]. In the present study, this variation has

Table 3. Basic descriptive statistics for the analysed variables in the male limbs group and in the female limbs group.

	Male limbs					Female limbs				
	Min [mm]	Max [mm]	Median [mm]	Arithmetic mean [mm]	SD [mm]	Min [mm]	Max [mm]	Median [mm]	Arithmetic mean [mm]	SD [mm]
LLE	740	824	792	785	29.2	638	764	704	706	33.4
TL	345	412	395	390	18	320	393	364	362	20.5
PSIS-IT	104	141	127	125	13.1	94	126	113	112	9
PSIS-GT	109	146	136	134	12	97	142	130	128	11.2
IT-GT	62	115	78	83	17.3	59	98	75	75	12.4
WPM	27	39	32	32	4.7	28	39	31	32	3
LUEPM	70	106	81	84	13.9	75	93	78	81	6.2
LLEPM	69	116	86	89	16.2	72	86	78	79	4.1
LESN-GT	21	52	44	40	10.9	22	50	35	36	8.7
MESN-IT	63	96	70	74	10.3	64	90	74	74	7.4
LSN-LEPM	15.5	28.2	23.2	22.3	5.2	10.1	32.5	15.7	16.7	5.8

Designations description as in Table 1.

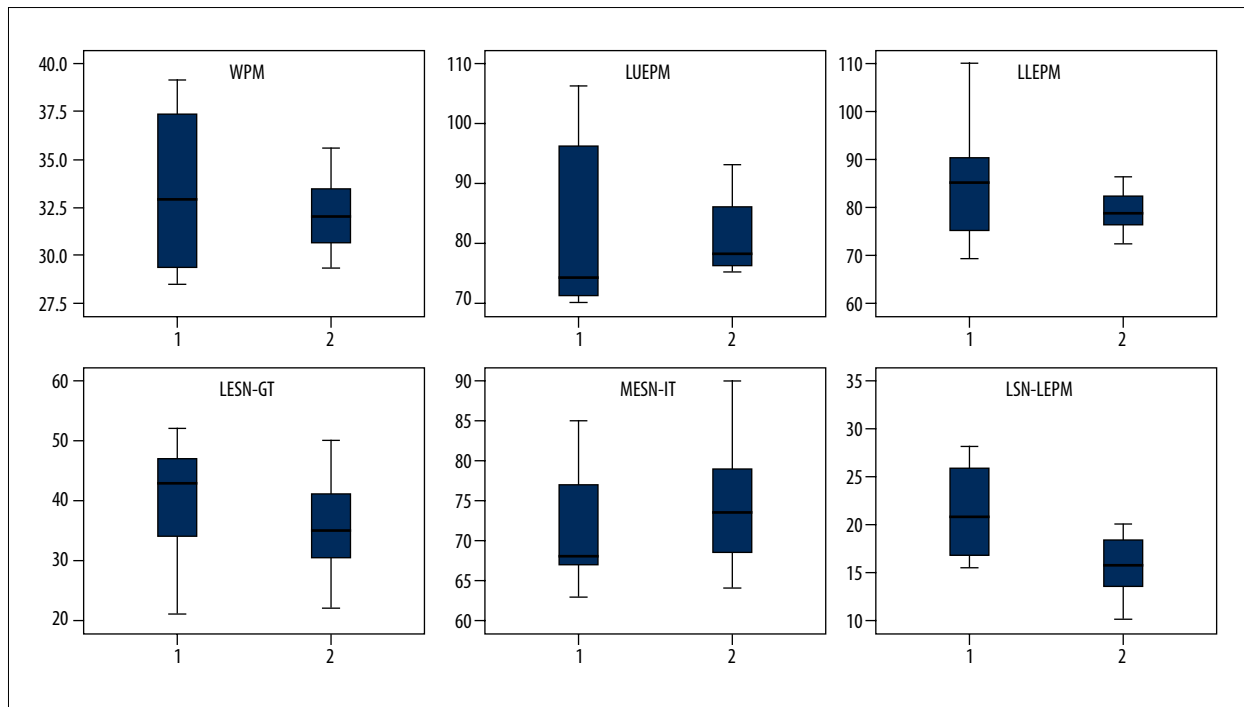


Figure 6. Comparison of dispersion of selected variables in the male limbs group (1) and in the female limbs group (2).

been observed in 20% of the limbs; however, in the literature the incidence of this variation varies. Natsis et al. found it in 4.1% of the studied limbs [9]. The authors point out that during a surgical procedure aiming at complete decompression of the sciatic nerve, the surgeon should take into account a

possibility that another tendon may be located ‘inferior or deep to the first one’ [9]. Okraszewska et al. recorded the variation in two out of 36 studied limbs of the Polish population (6%) [10], whereas Pokorný et al., in a study conducted on 91 cadavers in the Czech population, observed a variation in which

PM is perforated by one branch of the SN in 14.3% of the cases [11]. Güvençer et al. studied 25 male cadavers and found this anatomical relation in six cadavers (in one case it was bilateral and in five it was unilateral) [12]. Ogeng'o, in his research on variations of the sciatic nerve in the black Kenyan population, found that the tibial nerve passed always under PM (within the infra-piriform foramen), whereas the common peroneal nerve pierced the PM in 7.9% of cases [13]. In a study on 514 limbs Chiba found a variation with the common peroneal nerve passing through the PM in as many as 38% of cases, which is the highest rate reported in literature [14].

An atypical course of the SN in which two roots of the SN merge into one trunk below the inferior edge of the PM was observed by Ogeng'o et al. in 4.9% of cases [13], while Okraszewska et al. found it in three out of 36 examined limbs (8% of cases) [10]. This arrangement has been recorded in the present study in 10% of cases.

Moreover, in literature there are case reports of the SN branches wrapping around the PM in specimens with high division of the SN, so that the tibial nerve runs downwards (within the infra-piriform foramen), and the common peroneal nerve upwards from the PM (through the suprapiriform foramen). This type incidence according to different authors is: 1.5% of the examined cadavers (Ugrenovic et al.) [15], 2.4% (Ogeng'o et al.) [13], 6% of the examined specimens (Okraszewska et al.) [10], while Güvençer et al. found it in four out of 25 cadavers (in two of them it was unilateral and in two it occurred bilaterally) [12]. A rare case in which three roots of the SN merged into one common trunk only after exiting of the greater sciatic foramen (with the upper trunk running above and two trunks running below the PM) was described by Nayak et al. [16].

Bergman describes a possible fusion of the PM with other muscles, including the gluteus medius, the superior gemellus muscle and in rare cases with the obturator internus [8]. A fusion of the PM with the gluteus medius has been found in three limbs in our specimens, which accounts for 10% of the study material.

The matter of differences in the incidence of particular variations of the SN course in relation to the PM between the sexes remains to be settled. Okraszewska et al. have recorded no such differences [10], which is in line with our observations.

Taking into consideration the clinical problems, it seems probable that occurrence of anatomical differences in the SN course in relation to the PM may, according to some authors, contribute to piriformis syndrome, especially if accompanied by other etiological factors [5,17–19]. Chapman and Bakkum described a case of a male patient with low back pain and piriformis syndrome symptoms, whose MRI revealed an anomaly of the

PM – accessory superior bundles of the right piriformis [20]. Conservative treatment resulted in improvement, even though the structural cause of the ailment remained [20]. Chen, on the other hand, described a case of a 28-year-old female patient with a 'bipartite piriformis', which caused SN entrapment [17]. In this case, only recreation of normal relations of the SN to the PM by dissection of the lower head of the piriformis resolved the sciatica symptoms [17]. An 'accessory piriformis muscle' as a cause of piriformis syndrome, easily diagnosable with MRI, was described by Sen and Rajesh [19].

A few authors took into consideration anthropometric measurements of the PM in reference to different types of build and sex [2,21,22]. Güvençer et al. presented in 2008 morphometric data on the relationships between the sciatic nerve on the one hand, and the PM and selected bony landmarks in both neutral and test positions on the other hand; however, the study was conducted solely on male limbs [2]. Although it is true that this research was conducted in static conditions due to the specificity of the examined specimens, to the best of our knowledge it is the first work that attempts to present a morphometric analysis of the anatomical relations between the PM and SN with reference to anatomical variations of both these structures. So, in specimens with typical anatomical relations between the PM and the SN, certain regularities have been observed, but in the group of specimens with variations in the PM, on the contrary, the data are more diverse and the correlations between them much weaker. In view of the above, a possibility of considerable deviations from the expected topographic relations should be taken into account when interpreting sciatic neuropathy, but also during any invasive medical procedures in the gluteal region.

The research material has also revealed subtle differences in reference to sex. For a majority of parameters, there was less diversity in the female limbs group. There were several differences between the male and female pelvis (e.g., the female pelvis is more shallow and the sciatic notches are wider, and the male pelvis is taller and narrower with the acetabulum oriented more laterally [23,24]. So, slightly different correlations between particular anthropometric parameters in both sexes may result from differences in the structure of the pelvis.

Conclusions

Results of the conducted research, as well as the scientific literature review, point to the conclusion that there are several anatomical variations of the PM morphology and SN course within the deep gluteal region.

There are also statistically significant correlations between some anthropometric measurements in groups of male and

female limbs. For a majority of parameters, there is less diversity in the female limbs group. However, in this study there were no statistically significant differences revealed taking into

consideration the location of SN in reference to selected bony landmarks between limbs with a typical SN course and limbs with SN anatomical variations.

References:

- Lewis AM, Layzer R, Engstrom JW et al: Magnetic resonance neurography in extraspinal sciatica. *Arch Neurol*, 2006; 63: 1469–72
- Güvençer M, Akyer P, Iyem C et al: Anatomic considerations and the relationship between the piriformis muscle and the sciatic nerve. *Surg Radiol Anat*, 2008; 30: 467–74
- Miller TA, White KP, Ross DC: The diagnosis and management of Piriformis Syndrome: myths and facts. *J Neurol Sci*, 2012; 39: 577–83
- Ozaki S, Hamabe T, Muro T: Piriformis syndrome resulting from an anomalous relationship between the sciatic nerve and piriformis muscle. *Orthopedics*, 1999; 22: 771–72
- Parziale JR, Hudgins TH, Fishman LM: The Piriformis syndrome. *Am J Orthop*, 1996; 25: 819–23
- Sharma VK, H'ng MW: Congenital incomplete fusion of superior mesenteric artery mimicking dissection. *Am J Case Rep*, 2015; 16: 41–44
- Beaton LE, Anson BJ: The relation of the sciatic nerve and its subdivisions to the piriformis muscle. *Anat Rec*, 1937; 70: 1–5
- Bergman RA, Thompson SA, Afifi AK, Saadeh FA: Compendium of human anatomic variation: text, atlas, and world literature. Baltimore and Munich: Urban & Schwarzenberg, 1988
- Natsis K, Totlis T, Konstantinidis GA et al: Anatomical variations between the sciatic nerve and the piriformis muscle: a contribution to surgical anatomy in piriformis syndrome. *Surg Radiol Anat*, 2014; 36: 273–80
- Okraszewska E, Migdalski L, Jedrzejewski KS, Bolanowski W: Sciatic nerve variations in some studies on the Polish population and its statistical significance. *Folia Morphol*, 2002; 61: 277–82
- Pokorný D, Jahoda D, Veigl D et al: Topographic variations of the relationship of the sciatic nerve and the piriformis muscle and its relevance to palsy after total hip arthroplasty. *Surg Radiol Anat*, 2006; 28: 88–91
- Güvençer M, Iyem C, Akyer P et al: Variations in the high division of the sciatic nerve and relationship between the sciatic nerve and the piriformis. *Turk Neurosurg*, 2009; 19: 139–44
- Ogeng'o JA, El-Busaïdy H, Mwikia PM et al: Variant anatomy of sciatic nerve in a black Kenyan population. *Folia Morphol*, 2011; 70: 175–79
- Chiba S: Multiple positional relationships of nerves arising from the sacral plexus to the piriformis muscle in humans. *Kaibogaku Zasshi*, 1992; 67: 691–724
- Ugrenovic S, Jovanovic I, Krstic V et al: The level of the sciatic nerve division and its relations to the piriform muscle. *Vojnosanit Pregl*, 2005; 62: 45–49
- Nayak SB, George BM, Mishra S: A sciatic nerve with three roots and its perforation by the enlarged ischiadic artery. *Anat Sci Int*, 2014; 89: 118–21
- Chen WS: Bipartite piriformis muscle: an unusual cause of sciatic nerve entrapment. *Pain*, 1994; 58: 269–72
- Pecina HI, Boric I, Smoljanovic T et al: Surgical evaluation of magnetic resonance imaging findings in piriformis muscle syndrome. *Skeletal Radiol*, 2008; 37: 1019–23
- Sen A, Rajesh S: Accessory piriformis muscle: an easily identifiable cause of piriformis syndrome on magnetic resonance imaging. *Neurol India*, 2011; 59: 769–71
- Chapman C, Bakkum BW: Chiropractic management of a US Army veteran with low back pain and piriformis syndrome complicated by an anatomical anomaly of the piriformis muscle: a case study. *J Chiropr Med*, 2012; 11: 24–29
- Kulcu DG, Naderi S: Differential diagnosis of intraspinal and extraspinal non-discogenic sciatica. *Clin Neurosci*, 2008; 15: 1246–52
- Currin SS, Mirjalili SA, Meikle G, Stringer MD: Revisiting the surface anatomy of the sciatic nerve in the gluteal region. *Clin Anat*, 2015; 28(1): 144–49
- Rissech C, Garcia M, Malgosa A: Sex and age diagnosis by ischium morphometric analysis. *Forensic Science Int*, 2003; 135: 188–96
- Wang SC, Brede C, Lange D et al: Gender differences in hip anatomy: possible implications for injury tolerance in frontal collisions. *Annu Proc Assoc Adv Automot Med*, 2004; 48: 287–301